



## Safety and effectiveness of retrorectal presacral approach for lumbosacral axial instrumentation *A clinical study*

Alexander HADJIPAVLOU, Kalliopi ALPANTAKI, Pavlos KATONIS, Georgios VASTARDIS,  
Michael TZERMIADIANOS, Nikolaos BENARDOS

*From University Hospital of Heraklion and Asklipion Clinic Heraklion, Crete, Greece and Neo Athineon Clinic, Athens, Greece*

This prospective study aimed to quantify the risks and complications associated with AxiaLIF in a series of 29 patients. AxiaLIF is a fusion technique using a percutaneous retrorectal, presacral corridor approach to access the L5-S1 and L4-L5 intervertebral spaces transaxially, through the body of S1 and L5 vertebrae. The fusion rate in the present series was 92% and the reported results ranged from 68% to 100%. The only serious complication in the authors' series was one presacral haematoma (1/29, or 3.5%). Symptomatic subsidence occurred in the stand alone group, resulting in foraminal stenosis and radiculopathy in two patients (7%) and back pain in one (3.5%). Painful radiolucent halo around the rod was noted in a spondylolytic case (1/29, or 3.5%); it resolved after transpedicular instrumentation.

AxiaLIF is a novel truly minimally invasive technique not requiring blood transfusion and can be safely performed as a day surgery. Retroperitoneal haematoma, ureteral and vascular injuries can be avoided by respecting the regional anatomical landmarks as guided by accurate fluoroscopy. Only expanding haematomas may have to be drained. Bowel perforation can be prevented by gently sweeping away the rectum from the sacrum before inserting the guide probe.

**Keywords:** minimal invasive; AxiaLIF; spinal instrumentation; complications.

### INTRODUCTION

The conventional open surgical approaches for posterior lumbar interbody fusion (PLIF), anterior lumbar interbody fusion (ALIF) and intertransverse fusion (IF) are associated with several complications. More specifically IF is linked with extensive damage to the musculotendinous tissues predisposing to chronic back pain, long hospital stay, post-operative pain and morbidity and extensive blood loss and late return to normal activities (7,9,11,37).

- 
- Alexander Hadjipavlou, MD, MSc., FACS, FRCS(C), Professor of Orthopaedic Surgery.  
*University Hospital of Heraklion, Crete, Greece; Asklipion Clinic Heraklion, Crete, Greece; Neo Athineon Clinic, Athens, Greece.*
  - Kalliopi Alpantaki, MD, Orthopaedic Surgeon.
  - Pavlos Katonis, MD, Associate Professor of Orthopaedic Surgery.  
*University Hospital of Heraklion, Crete, Greece.*
  - Michael Tzermiadianos, MD, Orthopaedic Surgeon.  
*Asklipion Clinic Heraklion, Crete, Greece.*
  - Georgios Vastardis, MD, Orthopaedic Surgeon.
  - Nikolaos Benardos, MD, Orthopaedic Surgeon.  
*Neo Athineon Clinic, Athens, Greece.*

Correspondence: Alexander G. Hadjipavlou, Eleftherias Square 45, Electra's Building (1st floor), 71201 Heraklion, Crete, Greece. E-mail: ahadjipa@yahoo.com

© 2013, Acta Orthopædica Belgica.

Complications reported with PLIF are nerve root injuries, dural leak, dural and epidural scar tissues that predispose to remote neural complications. ALIF complications (31) include vascular and ureter damage, retrograde ejaculation, impotence, sympathetic dysfunction, deep vein thrombosis, pancreatitis, bowel injury. Furthermore, an access surgeon is required (31) by a good number of surgeons either because they are not well versed with the intricate anatomy of the region or for medicolegal reasons. For these reasons these procedures have been supplanted by three minimally invasive surgical procedures with maximized effects: transforaminal lumbar interbody fusion (TLIF), axial lumbar interbody fusion (AxiaLIF) and extreme lateral lumbar interbody fusion (XLIF). The advantages of minimally invasive procedures are decreased blood loss thus avoiding blood transfusion, decreased postoperative pain and morbidity, decreased hospital stay and medical cost and a faster return to normal activities.

Each of these procedures has its advantages and disadvantages. In this manuscript we will address the indications and pitfalls of the surgical technique associated with AxiaLIF.

AxiaLIF, a recently introduced minimally invasive spinal instrumentation, is a special threaded-rod device (TranS1, Wilmington NC, USA), designed to stabilize the lower lumbar spine, achieve fusion with minimal morbidity, shorten the hospital stay and avoid neural, vascular and musculotendinous injuries. This transsacral fusion technique using a percutaneous retrorectal, presacral corridor approach to access the L5-S1 and L4-L5 intervertebral spaces transaxially, through the body of S1 and L5 vertebrae (8) is an evolution of four previously reported techniques with similar objectives. One of the techniques described in a textbook by FW Ruthke consists of paraxial introduction of a rib strut through the sacrum, L5-S1 interspace, L5 vertebra, L4-L5 interspace to L4 vertebra (35). Another technique described by René Louis in 1996 for the treatment of L5-S1 instability particularly for spondylolisthesis involves an open paraxial approach at the lumbosacral spine using a fibular strut (16,23,28). A third technique entails a midline cage placement for L5-S1 fusion in spondylolisthesis through a sacral laminectomy (4). Finally, a fourth technique

was designed by McMillan *et al* (24) for fusion of L5-S1, through a percutaneous posterolateral approach.

The goals of this study are to evaluate the claims of safety and effectiveness of this procedure, to analyze the surgical complications encountered in our series and finally, to formulate and highlight useful information in order to render this novel approach safe and effective.

## MATERIAL AND METHODS

We conducted a prospective study of 29 patients – 21 women and 8 men – treated in our institutions over the past four years. The average age was 62.5 years (38-82). Indications for surgery are listed in table I. Surgery was performed at one level (L5-S1) in 25 patients and two levels (L5-S1 and L4-L5) in 4 patients. In the one level group, four patients underwent only AxiaLIF, (stand alone), in four the procedure was enhanced with facet screws and in 17 with pedicle screws. For the two-level fusion (L5-S1 and L4-L5) AxiaLIF was supplemented in all four patients with pedicle screws. Six of the patients were obese with body mass index (BMI) greater than 40. Of the one level L5-S1 fusion group that was enhanced with tranpedicle instrumentation, 3 had previous surgical procedures. Two were treated with L4-L5 XLIF and one with transpedicular L3-L4 & L4-L5 instrumentation. The follow-up period ranged from 24 months to 4 years. At six months, twelve months and 24 months, the patients were evaluated for clinical outcomes using the Oswestry Disability Index (ODI) (17) for function and the visual analogue scale (VAS) for pain. Assessment for fusion and technical complications, such as loosening of instrumentation, subsidence, vertebral fracture, compromise of spinal alignment, haematomas and other surgical failures were investigated using post-operative thin-slice CT scans (at 6 months and 12 months) and dynamic radiographs in flexion-extension at 6 months. Comparison between the groups was made with one way ANOVA. The significance level was set at  $p < 0.05$ .

## RESULTS

The average surgical time for one level AxiaLIF was 50 min, for a stand-alone procedure, 90 min when surgery was enhanced with a transfacet screw fixation and 110 min when supplemented with transpedicular screw instrumentation. The corresponding surgical time for a two-level stand-alone

Table I. — Indications for surgery

Pathology		No patients
LBP associated with disk collapse		6
LBP & SCIATICA associated with disk collapse		16
Spondylolytic spondylolisthesis	Grade I	2
	Grade II	2
As an adjunct to scoliosis surgery for L5-S1 fusion		2
LBP after interspinal spacer for spinal stenosis		1

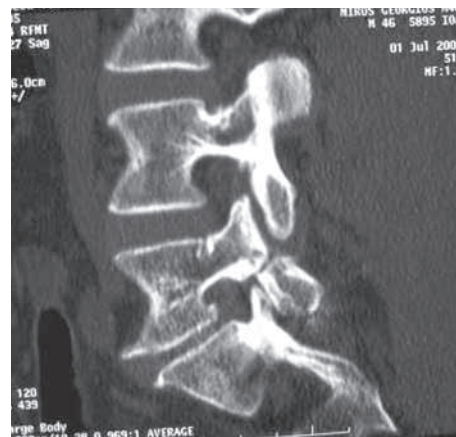LBP = Low Back Pain.

AxiaLIF was 90 min and 3 hours when supplemented with transpedicular screw instrumentation. Blood loss for AxiaLIF alone was less than 50 ml and when augmented with the transpedicular screw instrumentation between 100 to 200 ml. Blood loss for transfacet screw fixation was minimal. The post-operative hospital stay was up to 24 hours for one level AxiaLIF, and between 48 hours to 72 hours for two-level instrumentation. The extra morbidity time can be attributed to the transpedicular screw instrumentation, since for the AxiaLIF with or without transfacet screw fixation most of the patients were ready to leave the hospital after recovery from anaesthesia.

There was an average 50 mm ( $p < 0.001$ ) decrease in VAS scores (from 75 mm to 25 mm,  $p < 0.001$ ) and 33 points (from 55% to 22%,  $p < 0.001$ ) in Oswestry scores, between preoperative and post-operative clinical assessment at 3 months that was almost sustained at 6, 12 and 24 months follow-up in 25 patients; one patient was lost to follow-up at 12 months and three more at 18 months.

One patient developed retroperitoneal presacral haematoma 4 days after surgery. He presented with symptoms consisting of a gradual onset of abdominal cramps and discomfort associated with night sweats and low-grade fever in the evenings that lasted for two weeks. Bowel movement was not affected. CT-scan revealed presacral haematoma; ESR, CRP and complete blood count were moderately elevated. The patient was treated empirically with oral antibiotics and he recovered completely after 2 weeks.

Another patient with spondylolysis (treated with AxiaLIF and transfacet screws) developed a painful

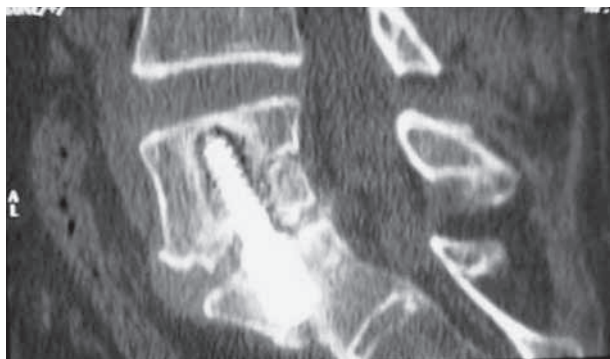

*Fig. 1.* — CT images demonstrate spondylolysis that was missed preoperatively. The patient developed low back pain 3 months after surgery.

radiolucent halo around the threaded rod which manifested with low back pain four months after surgery. Complete healing of the osteolysis around the threaded rod was achieved after posterior transpedicular instrumentation and fusion (Fig. 1, 2 & 3).

Three patients from the stand-alone group developed subsidence manifesting as a back pain in one patient and L5 radiculopathy in two. The former was treated with posterior percutaneous transpedicle instrumentation and the latter two patients responded well with decompressive foraminotomy and percutaneous transpedicle instrumentation.

One obese patient exhibited superficial skin burn from inadvertent use of the cautery and this resulted in wound dehiscence, which healed satisfactorily with local wound dressings. Otherwise, all obese patients responded very well to this procedure.



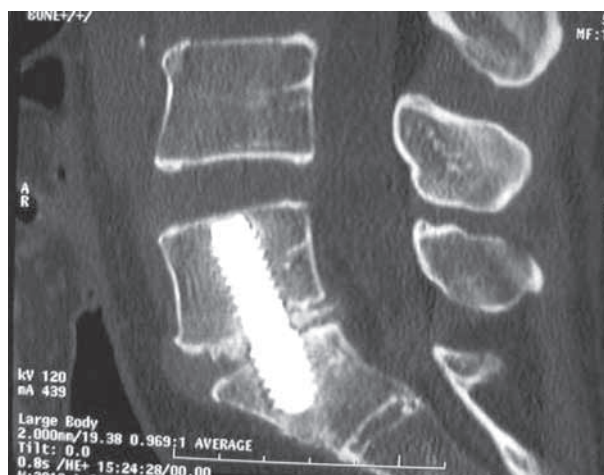**Fig. 2.** — Lateral CT images demonstrating bone resorption halo around the rod 6 months after surgery.

Two patients demonstrated inadequate fusion at L5-S1 interbody space, as observed at one and two years follow-up. However, they were asymptomatic in their clinical assessment. Therefore, the fusion rate was 92% (23 out of 25 patients). In this series no other serious or minor complications were encountered.

## DISCUSSION

AxiaLIF is a truly tissue sparing approach in terms of maintaining the lumbosacral supporting musculotendinous structures. The damage to the lumbosacral paraspinal musculature is attributed to the transpedicular instrumentation, which, however, can be of minor importance if a minimal muscle splitting technique, or percutaneous insertion is used. This procedure has advantages over other procedures, since no annular damage to the intervertebral disc is inflicted, the anterior and posterior longitudinal ligaments are not violated, and the facet joints are not compromised (8). The preservation of these structures, which are integral for spinal stability, give significant biomechanical advantage over the other interbody devices necessitating the sacrifice of crucial musculoligamento-osseous structures (20,21).

AxiaLIF is also quite effective for correcting and stabilizing grade I and II spondylolisthesis as demonstrated by Rodgers *et al* in a series of 79 patients (33).

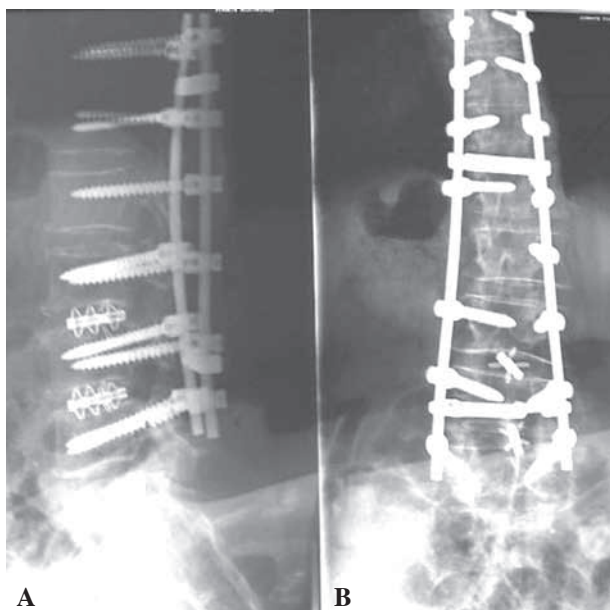


**Fig. 3.** — Twelve months later CT scan exhibits excellent bone accretion filling the osteolytic halo around the threaded-rod (C and D).

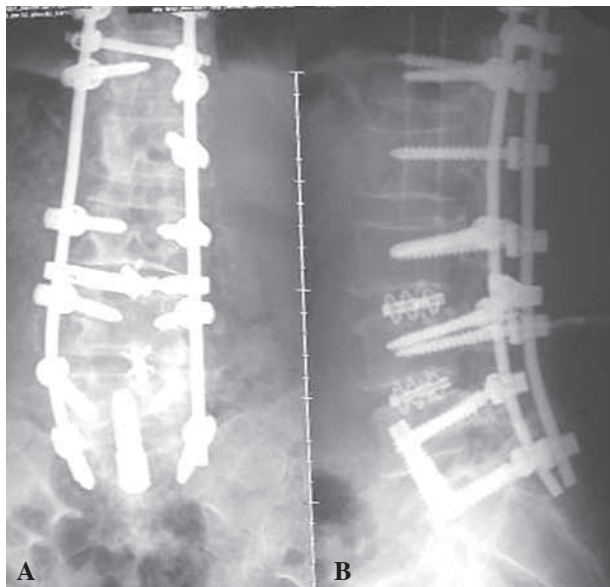
For obese patients, AxiaLIF is a convenient procedure because it avoids extensive dissection and necrosis of fat tissue. After treating 91 obese patients (BMI > 30), including 27% patients with morbid obesity (BMI > 38), Rodgers *et al* concluded that AxiaLIF is safe and useful for obese patients (34).

Long scoliosis surgery with extension to the sacrum is associated with high complication rate of pseudoarthrosis (13,14). Supplementation with AxiaLIF, as an adjunct procedure, to stabilize the L5-S1 level, is a convenient expedience because of its minimal blood loss and short operating time (3) (Fig. 4 & 5) as opposed to other interbody fusion techniques (10).

Biomechanical testing adds support to the notion that this device should be avoided as a stand-alone, particularly in the presence of spondylolysis, and should be augmented with posterior instrumentation as in the ALIF, PLIF & TLIF situation (21). Bone resorption surrounding the axial rod that occurred in one of our patient (Fig. 2) was probably due to excessive motion of an unstable segment (L5-S1 spondylolysis), (Fig. 1) that healed after posterior transpedicle stabilization (Fig. 3). This can further be supported by biomechanical data suggesting that enhancement of transaxial rod fixation with posterior instrumentation results in higher construct stability and successful fusion (2,15).

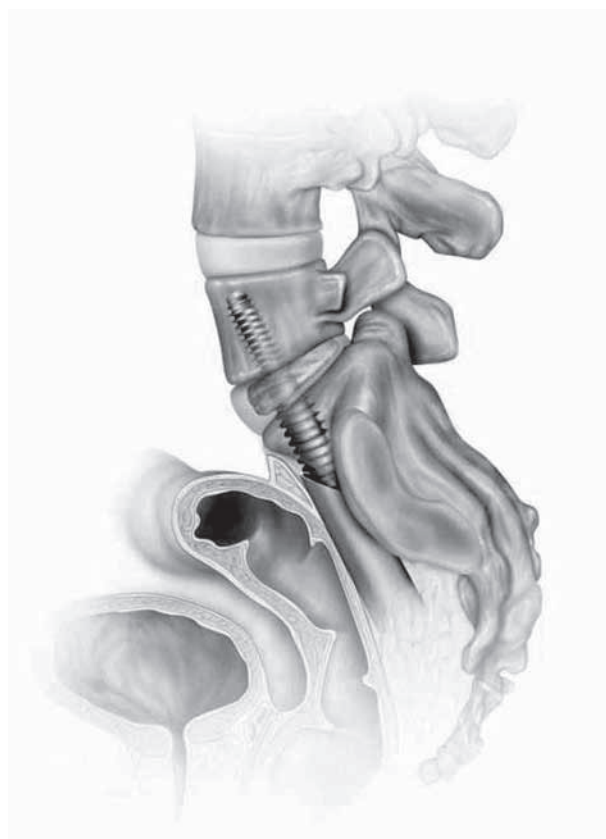


**Fig. 4.** — **A.** Lateral and **B.** anteroposterior views of a patient with flat back syndrome (back pain and fatigue), left L5 radiculopathy and broken L5 screw.



**Fig. 5.** — **A.** Anteroposterior and **B.** lateral X-ray views demonstrate correction of lumbar alignment after revision with L5-S1 AxiALIF and extension of the transpedicle instrumentation to S1 level.

The lumbar lordotic curve, at L5-S1 level, can be improved by placing the AxialIF threaded rod, which has a variable thread count, more anteriorly

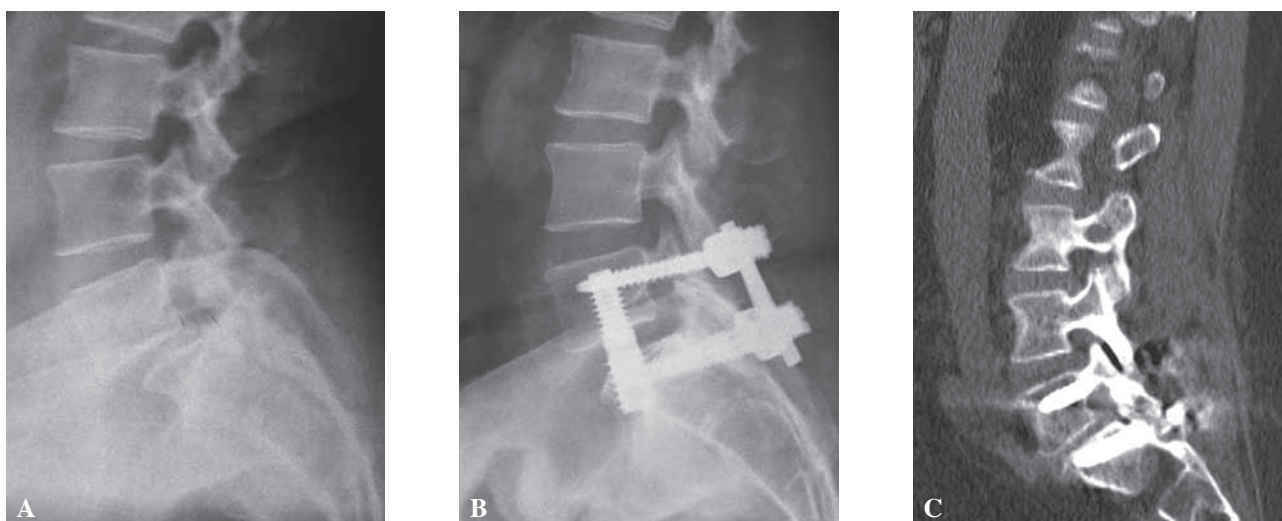


**Fig. 6.** — Note that the L5-S1 lordotic curve can be restored by placing the AxiALIF threaded rod, with variable thread count, more anteriorly in order to allow differential distraction between anterior (more) and posterior (less) intervertebral disc space.

in order to allow a differential distraction between anterior (greater distraction) and posterior (lesser distraction) intervertebral disc space (Fig. 6).

Subsidence, as occurred in our patient, may provoke compressive radiculopathy. Posterior stabilization with pedicle screws may have some effect but apparently cannot prevent altogether some asymptomatic subsidence, which apparently is not an infrequent occurrence (32) (Fig. 7). Potentially, subsidence may be prevented by purchasing securely the base of the threaded rod in the cortical bone of the S2 sacral segment. Furthermore, overdistracted should be avoided particularly in osteoporotic patients.

Presacral or retroperitoneal haematoma is not strange occurrence in anterior spine procedures or



**Fig. 7.** — **A.** A 44-year-old woman with morbid obesity, low back pain and right L5 radiculopathy caused by grade I spondylolytic spondylolisthesis and foraminal stenosis. **B.** She underwent AxiALIF anteriorly and transpedicular fixation posteriorly. Note the reduction of spondylolisthesis and distraction L5-S1 disc space. **C.** Twelve months post-surgery the patient remains completely asymptomatic, however, the CT scan reveals some subsidence.

various general surgical, urological and gynecological procedures. Most of the time, small amounts of blood will be re-absorbed in a matter of a few days to weeks (5). Less than 1% of patient is expected to develop symptomatic haematoma consisting of decreased haemoglobin and haematocrit, bloody discharge, sacral pain even compression of the rectum and urinary bladder (1). On CT-scan the haematoma is usually demonstrated as a hyper-dense mass in the presacral area (22). The origin of presacral haematoma in AxialLIF surgery has not been documented with certainty. Small vessels can be disrupted when dissecting through the pre-sacral fat tissue (1). Premature draining of the haematoma may risk further excessive bleeding caused by rupture of the tamponated haematoma. Only an expanding pelvic haematoma with unstable vital signs should be addressed aggressively. In a series of 285 patients, reported by Smith *et al* (36), only two out of 5 patients who developed retroperitoneal haematoma required re-exploration and drainage. It is important for the surgeon to be familiar with the anatomical landmarks in the region. The midpre-sacral coronal safe zone dissection is limited laterally by the iliac vessels and ureter, which should not be violated during the process of instrumentation.

For S1-S2 levels this ranges between 6.5 cm to 6.9 cm for males and 5.4 cm to 6.8 cm in females. Distal to S1-S2 the hypogastric nerve and parasympathetic nerves are located several centimeters lateral to the midline, and therefore are not at risk (26,38). The mean sagittal distance from the anterior sacral margin to the rectum at S1, S2, and S3 levels was reported for men to be 16.2 mm, 14.9 mm and 13 mm respectively and the corresponding figures for women are 11.9 mm, 12.2 mm and 10.6 mm (29).

The most dreadful complication of AxialLIF is rectal perforation. Documented statistics have not been published except in one case report (6) and one case series of 50 patients (5). The signs and symptoms of rectal injury are hypogastric pain, nausea and melaena (6). Compatible findings with rectal perforation on CT-scan are presacral soft tissue fluid density with fat stranding, extraluminal rectal contrast and gas within the areas of soft tissue enhancement (6).

Certain medical situations such as previous rectal or perirectal surgery, pelvic radiotherapy and anterior transperitoneal or retroperitoneal spinal approach are considered absolute contraindications for AxialLIF. Relative contraindications are Crohn's procti-

tis, ulcerative colitis, diverticulitis and full-thickness rectal prolapse. A history of intra-abdominal infections such as appendicitis, or a pelvic inflammatory disease predispose to rectal injury (5,6,25,30). Open or minimally invasive anterior and retroperitoneal approaches to the lumbar spine have also been reported to provoke intestinal adhesions (12,18,19,27). Smith *et al* have not encountered rectal injuries, in a large series of 285 consecutive cases (36). Preoperatively, all patients should undergo full mechanical bowel preparation the day before the procedure. Parenteral prophylaxis against both aerobic and anaerobic microbial organism should be given prior to skin incision. Rectal injury was reported to respond satisfactorily with temporary diversionary ileostomy or colostomy and a course of IV antibiotics (5,29). Primary colonoscopic repair can be successful if the diagnosis of bowel injury is made preoperatively. The main objective of this clinical study was to scrutinize the complications of this procedure in our series in order to establish technical guidelines for avoiding potential pitfalls and render AxiaLIF a safer procedure. It remains to determine its level of effectiveness in relation to other techniques in controlled randomized studies. The post-operative morbidity is minimal and the patient can be ambulatory soon after the recovery period from anaesthesia and hospitalization is less than 24 hours for one level fusion. Its minimal tissue damage also renders this procedure safe for the elderly patients (36). Since in our series we encountered no serious complications, and the fusion rate is relatively high, this suggests encouraging perspectives.

## REFERENCES

1. Afonso CT, Procópio RJ, Navarro TP *et al*. Ruptured internal iliac artery aneurysm : case report. *J Vasc Bras Porto Alegre*, 2009 ; 20 : 1.
2. Akesen B, Wu C, Mehbod AA, Transfeldt EE. Biomechanical evaluation of paracoccygeal transsacral fixation. *J Spinal Disord Tech* 2008 ; 21 : 39-44.
3. Anand N, Baron E, Thaiyananthan G, Khalsa K, Goldstein T. Novel minimally invasive multi-level percutaneous correction and fusion for adult lumbar degenerative scoliosis – A technique and feasibility study. *J Spinal Disord Tech* 2008 ; 21 : 459-467.
4. Bartolozzi P, Sandri A, Cassini M, Ricci M. One-stage posterior decompression-stabilization and trans-sacral interbody fusion after partial reduction for severe L5-S1 spondylolisthesis. *Spine* 2003 ; 28 : 1135-1141.
5. Bohinski RJ, Jain VV, Tobler WD. Presacral retroperitoneal approach to axial lumbar interbody fusion, a new, minimally invasive technique at L5-S1 : Clinical outcomes, complications and fusion rates in 50 patients at 1-year follow up. *SAS Journal* 2010 ; 4 : 54-62.
6. Botolin S, Agudelo J, Dwyer A, Patel V, Burger E. High rectal injury during trans-1 axial lumbar interbody fusion L5-S1 fixation : a case report. *Spine (Phila Pa 1976)* 2010 ; 15 ; 35(4) : E144-148.
7. Carreon LY, Puno RM, Dimar JR 2nd, Glassman SD, Johnson JR. Perioperative complications of posterior lumbar decompression and arthrodesis in older adult. *J Bone Joint Surg* 2003 ; 85-A : 2089-2092.
8. Cragg A, Carl A, Casteneda F *et al*. New percutaneous access method for minimally invasive anterior lumbosacral surgery. *J Spinal Disord Tech* 2004 ; 17 : 21-28.
9. DeBerard MS, Masters KS, Colledge AL, Schleusener RL, Schlegel JD. Outcomes of posterolateral lumbar fusion in Utah patients receiving workers' compensation : a retrospective cohort study. *Spine (Phila 1976)* 2001 ; 26 (7) : 738-746 ; discussion 747.
10. DeWald CJ, Stanley T. Instrumentation-related complications of multilevel fusions for adult spinal deformity patients over age 65 : Surgical considerations and treatment options in patients with poor bone quality. *Spine* 2006 ; 31 : S144-S151.
11. Deyo RA, Cherkin DC, Loeser JD, Bigos SJ, Ciol MA. Morbidity and mortality in association with operations on the lumbar spine. The influence of age, diagnosis, and procedure. *J Bone Joint Surg* 1992 ; 74-A : 536-543.
12. Diamond MP, Freeman ML. Clinical implications of postsurgical adhesions. *Hum Reprod Update* 2001 ; 7 : 567-576.
13. Edwards CC 2nd, Bridwell KH, Patel A *et al*. Thoracolumbar deformity arthrodesis to L5 in adults : the fate of the L5-S1 disc. *Spine (Phila Pa 1976)* 2003 ; 28 : 2122-2131.
14. Emami A, Deviren V, Berven S *et al*. Outcome and complications of long fusions to the sacrum in adult spine deformity : Luque-Galveston, combined iliac and sacral screws, and sacral fixation. *Spine (Phila Pa 1976)* 2002 ; 27 : 776-786.
15. Erkan S, Wu C, Mehbod AA *et al*. Biomechanical evaluation of a new AxiaLIF technique for two-level lumbar fusion. *Eur Spine J* 2009 ; 18 : 807-814.
16. Esses SI, Natout N, Kip P. Posterior interbody arthrodesis with a fibular strut graft in spondylolisthesis. *J Bone Joint Surg* 1995 ; 77-A : 172-176.
17. Fairbank JC, Couper J, Davies JB, O'Brien JP. The Oswestry low back pain disability questionnaire. *Physiotherapy* 1980 ; 66 : 271-273.
18. Frantides CT, Zeni TM, Phillips FM *et al*. L5-S1 Laparoscopic anterior interbody fusion. *JSLs* 2006 ; 10 : 488-492.

19. **Gumbs AA, Hanan S, Yue JJ, Shah RV, Sumpio B.** Revision open anterior approaches for spine procedures. *Spine J* 2007 ; 7 :280-285.
20. **Ledet EH, Carl AL, Cragg A.** Novel lumbosacral axial fixation techniques. *Expert Rev Med Devices* 2006 ; 3 : 327-334.
21. **Ledet EH, Tymeson MP, Salerno S, Carl AL, Cragg A.** Biomechanical evaluation of a novel lumbosacral axial fixation device. *J Biomech Eng* 2005 ; 127 : 929-933.
22. **Llauger J, Palmer J, Pérez C et al.** The normal and pathologic ischiorectal fossa at CT and MR imaging. *Radiographics* 1998 ; 18 : 61-82 ; quiz 146.
23. **Louis RP.** Lumbopelvic fusion. In *Lumbosacral and Spinopelvic Fusion*. 1996. Lippincott-Raven, Philadelphia.
24. **Macmillan M, Fessler RG, Gillepsy M, Montgomery WJ.** Percutaneous lumbosacral fixation and fusion. Anatomic study and two-year experience with a new method. *Neurosurg Clin N Am* 1996 ; 7 : 99-106.
25. **Marana R, Rizzi M, Muzii L et al.** Correlation between the American Fertility Society classifications of adnexal adhesions and distal tubal occlusion, salpingoscopy, and reproductive outcome in tubal surgery. *Fertil Steril* 1995 ; 64 : 924-929.
26. **Marotta N, Cosar M, Pimenta L, Khoo LT.** A novel minimally invasive presacral approach and instrumentation technique for anterior L5-S1 intervertebral discectomy and fusion. *Neurosurg* 2006 ; 20 (1) : E9.
27. **McAfee PC, Regan JJ, Geis WP, Fedder IL.** Minimally invasive anterior retroperitoneal approach to the lumbar spine. Emphasis on the lateral BAK. *Spine (Phila Pa 1976)* 1998 ; 23 : 1476-1484.
28. **Meyers AM, Noonan KJ, Mih AD, Idler R.** Salvage reconstruction with vascularized fibular strut graft fusion using a posterior approach in the treatment of severe spondylolisthesis. *Spine* 2001 ; 26 : 1820-1824.
29. **Oto B, Peynircioglu M, Eryilmaz A et al.** Determination of the width of the presacral space on magnetic resonance imaging. *Clin Anat* 2004 ; 17 : 14-16.
30. **Perry JF Jr, Smith GA, Yonehiro EG.** Intestinal obstruction caused by adhesions ; a review of 388 cases. *Ann Surg* 1995 ; 142 : 810-816.
31. **Rajaraman V, Vingnan R, Roth P, Heary RF, Conklin L, Jacobs GB.** Visceral and vascular complications resulting from anterior lumbar interbody fusion. *J Neurosurg* 1999 ; 91 : 60-64.
32. **Rodgers WB, Cox CS, Gerber EJ.** Safety and the learning curve of Trans-Sacral Fusion in the first 165 surgeries of a single surgeon series. Feb. 17-20, 2010 ; CNS meeting 26th annual meeting of the AANS-CNS Section on disorders of the spine and peripheral nerves, Rosen Shingle Creek, Orlando, Florida.
33. **Rodgers WB, Gerber EJ, Patterson JR BS.** Single level fusion for a grade I and grade II spondylolisthesis correction using the AxiALif rod system. 17-20 Feb 2010 ; CNS meeting 26th annual meeting of the AANS-CNS Section on disorders of the spine and peripheral nerves, Rosen Shingle Creek, Orlando, Florida.
34. **Rodgers WB, Gerber EJ, Patterson JR BS.** Transacral Interbody fusion (AxiALIF) in obese patients. 17-20 Feb 2010 ; CNS meeting 26th annual meeting of the AANS-CNS Section on disorders of the spine and peripheral nerves, Rosen Shingle Creek, Orlando, Florida.
35. **Ruthke FW, Schlegel KF.** *Orthopedisch-Chirurgisches Operationatlas*. Bond III Wirbelsäule und Becken. *Georg Thieme Verlag*, Stuttgart, 1974.
36. **Smith WD, Rodgers WB, Patterson J, Malone K.** AxiALIF complications in 285 consecutive cases. Apr 27-30, 2010 ; SAS 10 Annual Conference- International Society for the Advancement of Spine Surgery, Abstract 337, New Orleans, Louisiana.
37. **Stauffer RN, Coventry MB.** Posterolateral lumbar-spine fusion. Analysis of Mayo Clinic series. *J Bone Joint Surg* 1972 ; 54-A : 1195-1204.
38. **Yuan PS, Day TF, Albert TJ et al.** Anatomy of the percutaneous presacral space for a novel fusion technique. *Spinal Disord Tech* 2006 ; 19 : 237-241.